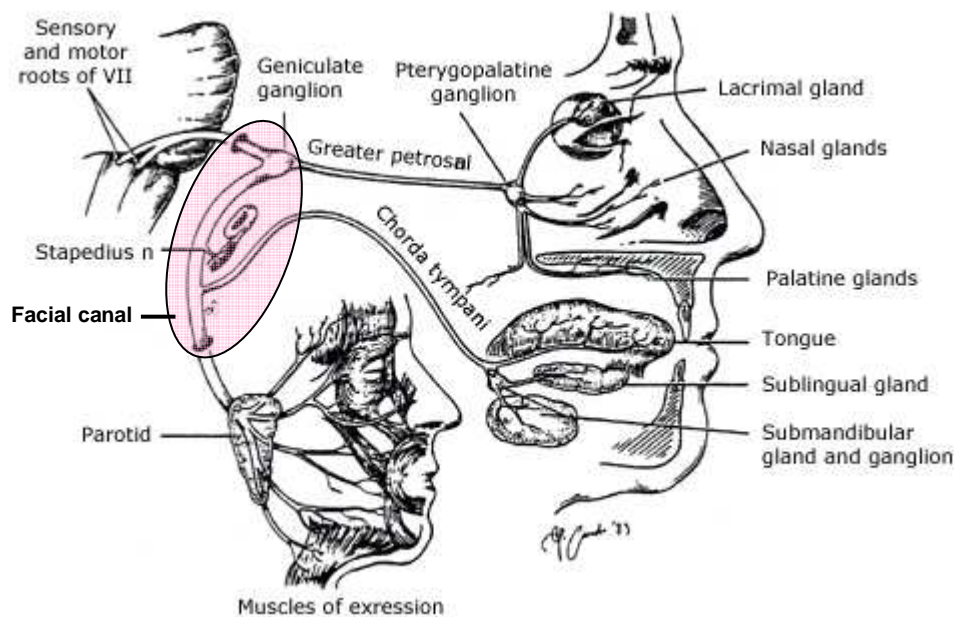


## Neuroanatomy

The VIIth cranial (facial) nerve is largely motor in function (some sensory fibres from external acoustic meatus, fibres controlling salivation and taste fibres from the anterior tongue in the chorda tympani branch). It also supplies the stapedius. From the facial nerve nucleus in the brainstem, fibres loop around the VI nucleus before leaving the pons medial to VIII and passing through the internal acoustic meatus. It passes through the petrous temporal bone in the facial canal, widens to form the geniculate ganglion (taste and salivation) on the medial side of the middle ear whence it turns sharply (and the chorda tympani leaves), to emerge through the stylomastoid foramen to supply all the muscles of facial expression including platysma.



## Presentation

Weakness of the muscles of facial expression and eye closure. Face sags and is drawn across to opposite side on smiling. Voluntary eye closure may not be possible and can produce damage to conjunctiva and cornea.

- In partial paralysis, lower face is generally more affected.
- In severe cases, there is often loss of taste over front of tongue and intolerance to high pitched or loud noises. May cause mild dysarthria and difficulty with eating.

House-Brackmann scale, (1=normal power,6=total paralysis) describes the degree of paralysis.

## Aetiology

Upper or lower motor neurone lesion?

- In a LMN lesion the patient can't wrinkle their forehead (unless a lesion in the parotid spares the temporal branch) - the final common pathway to the muscles is destroyed. Lesion in pons, or outside brainstem (post. fossa, bony canal, middle ear or outside skull).
- In an UMN lesion, the upper facial muscles are partially spared because of alternative pathways in the brainstem (unless bilateral lesion). Different pathways for voluntary and emotional movement. CVA's usually weaken voluntary movement often sparing involuntary movements (e.g. spontaneous smiling). The much rarer selective loss of emotional movement is called mimic paralysis and is usually due to a frontal or thalamic lesion.

Lower Motor Neurone =Bell's Palsy	Upper Motor Neurone
Idiopathic	Cerebrovascular disease
Infective <ul style="list-style-type: none"> <li>• Herpes simplex virus (type 1) - most common,</li> <li>• Herpes zoster (Ramsay-Hunt syndrome),</li> <li>• Other viruses - CMV, EBV, Coxsackie</li> <li>• Lyme disease</li> <li>• Otitis media or cholesteatoma</li> </ul>	Intracranial tumours
Trauma <ul style="list-style-type: none"> <li>• E.g. fractures of skull base, haematoma post-acupuncture</li> </ul>	Multiple sclerosis
Neurological <ul style="list-style-type: none"> <li>• Multiple sclerosis,</li> <li>• Guillain-Barré,</li> <li>• Mononeuropathy - e.g. due to DM, sarcoidosis, or amyloidosis</li> </ul>	Syphilis
Neoplastic <ul style="list-style-type: none"> <li>• Posterior fossa tumours,</li> <li>• Parotid gland tumours</li> <li>• Leukaemia</li> </ul>	HIV
Sjogren's syndrome	Vasculitides
Hypertension and eclampsia	
?Inactivated intranasal influenza vaccine	
Melkersson's syndrome (recurrent facial palsy, chronic facial oedema of face and lips, and hypertrophy/fissuring of the tongue)	

- If bilateral particularly consider Guillain-Barre or Lyme disease.
- If recurrent particularly consider lymphoma, sarcoidosis, and Lyme disease.
- In children particularly consider Lyme and middle ear disease.

### Characteristic features

#### *Acute LMN palsy*

Most frequently seen at 20-50 years, M=F. Incidence ~30/100,000 per year, higher in pregnant women (45/100,000). Usually rapid onset of unilateral facial paralysis. Aching pain below ear or in mastoid area is common and may suggest middle ear or herpetic cause if severe. There may be hyperacusis, and patients with lesions proximal to the geniculate ganglion/chorda tympani may be unable to produce tears and have loss of taste. If idiopathic then termed a Bell's Palsy.

#### *Bell's palsy*

Originally described by Sir Charles Bell in 1821. Incidence 20/100,000 between 10-40 years, but 59/100,000 over 65 years. Recent work suggests that a large number of these cases may be due to herpetic viral infection - particularly HSV 1, or Varicella (herpes) Zoster.

#### *Ramsay-Hunt syndrome*

LMN facial nerve palsy specifically due to Varicella (herpes) zoster. Pain is often a prominent feature and vesicles are seen in the ipsilateral ear, on the hard palate, and/or on the anterior two thirds of the tongue. It can include deafness and vertigo, and other cranial nerves can be affected. When the rash is absent it is known as zoster sine herpette.

## Investigations

- FBC (assoc with leukaemia), serology - Lyme, herpes and zoster (paired samples 4-6 weeks apart). ?use as probably won't influence management.
- Check BP in children with Bell's palsy (2 case reports of aortic coarctation).
- The following tests are rarely done but combined with a good understanding of the neuroanatomy can determine the level of the palsy:
  - Schirmer tear test (reveals reduced flow of tears from an affected greater palatine nerve).
  - Stapedial reflex (an audiological test absent if stapedius muscle is affected).
  - Electrodiagnostic studies (generally a research tool) reveal no changes in involved facial muscles for the first three days, but a steady decline of electrical activity often occurs over the next week, and will identify the 15% with axonal degeneration.

## Management

Ideally this should be a multidisciplinary approach, encompassing ophthalmologists, ENT, plastic surgeons and psychologists.

### *General measures*

- Reassurance - the majority of cases resolve spontaneously - see prognosis.
- Eye care - lubricating drops hourly and eye ointment at night ± eye patch. **Botulinum toxin** or surgery (upper lid weighting or tarsorrhaphy) may also be required temporarily.

### *Bell's palsy management*

- **Steroids** - **prednisolone** (1-2mg/kg/day - adult 60-80 mg/day - can divide dose bd) PO 5-10d within 72h is of proven benefit.
- **Antivirals** - No evidence that using antivirals as monotherapy is better than placebo. Combination therapy with steroids has no or only marginal benefit in meta-analyses. Where suspicion of herpes viral infection is high (vesicular rash, virus identified) **valacyclovir** (1g PO q8h) in addition to prednisolone might be considered by some.
- **Surgery** - Surgical transmastoid decompression of the facial nerve in severe cases is being investigated. Cosmetic surgery or anastomosis of hypoglossal nerve to the facial nerve may help if nerve fails to regenerate.

## Prognosis

71% of untreated patients with idiopathic non progressive Bell's palsy recover completely (84% have near-normal function) usually within a few weeks.

Poor prognostic features:

- Complete palsy or severe degeneration (electrophysiology)
- No signs of recovery by three weeks
- Age >60
- Severe pain
- Ramsay Hunt syndrome (herpes zoster virus)
- Associated with either hypertension, diabetes, or pregnancy

Recurrence: 8-10%.

Those with axonal degeneration may not show any re-innervation for three months, and recovery may be partial or not at all. Following this synkinesis is often seen e.g. blinking causes angle of mouth to contract. Also gustatory lacrimation ('crocodile tears'). Symptoms can be helped by subcutaneous or intramuscular injections of botulinum toxin.